

ФИО: _____

Пол: **Мужской**

Возраст: **51**

Вес: **116**

Рост: **182**

Дата: **2020-12-30**

Время: **10:58:16 UTC+3**

ЧСС: **79/мин**

ЧСС мин.: **72/мин**

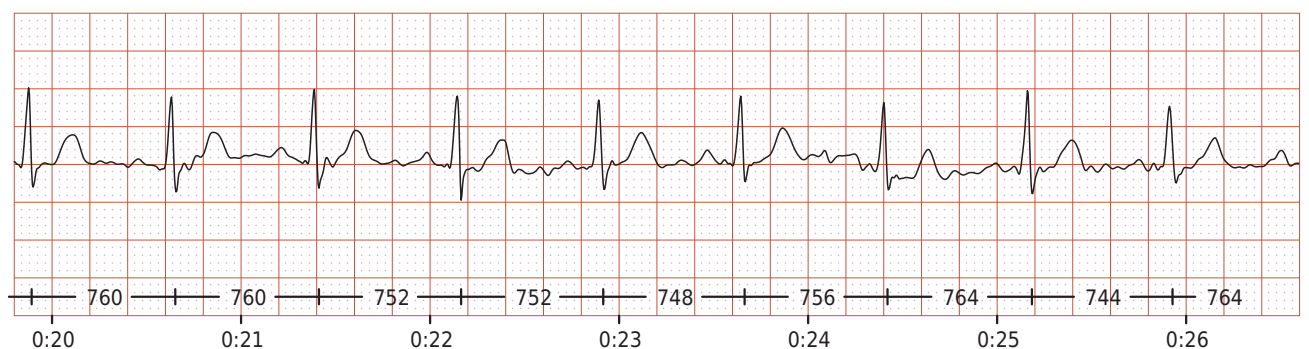
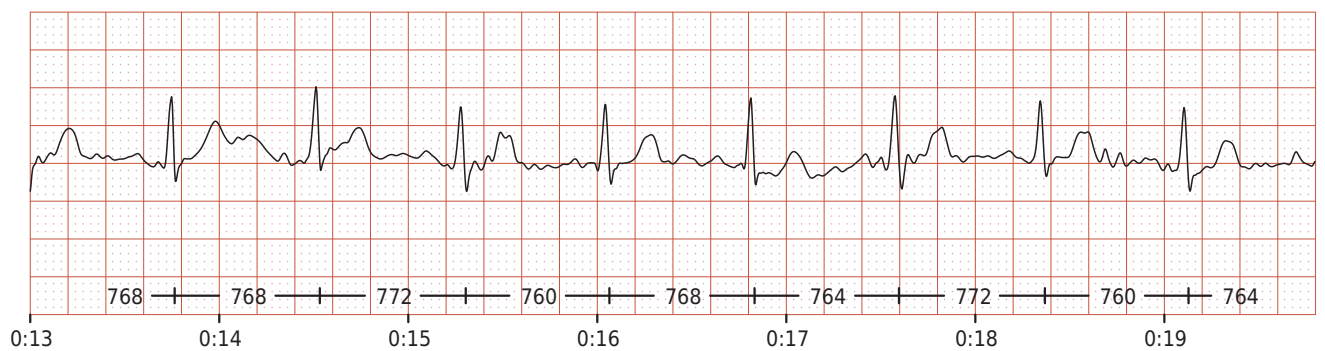
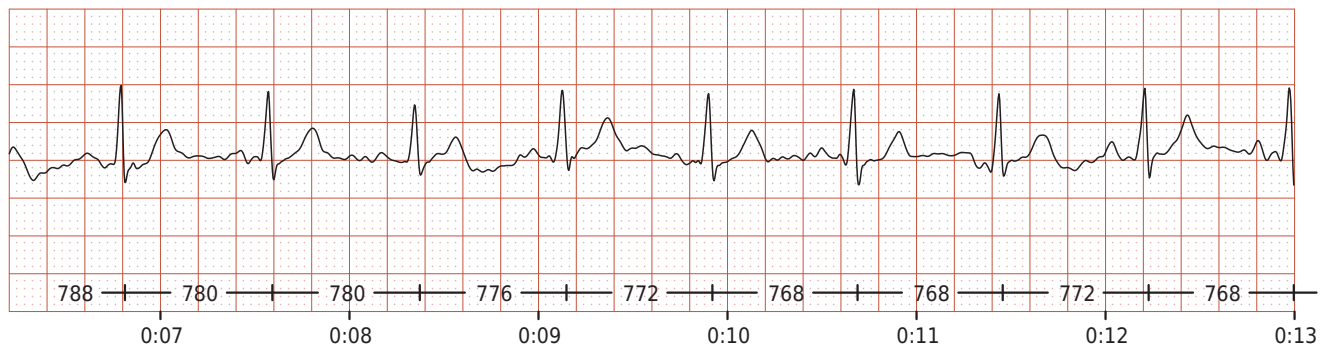
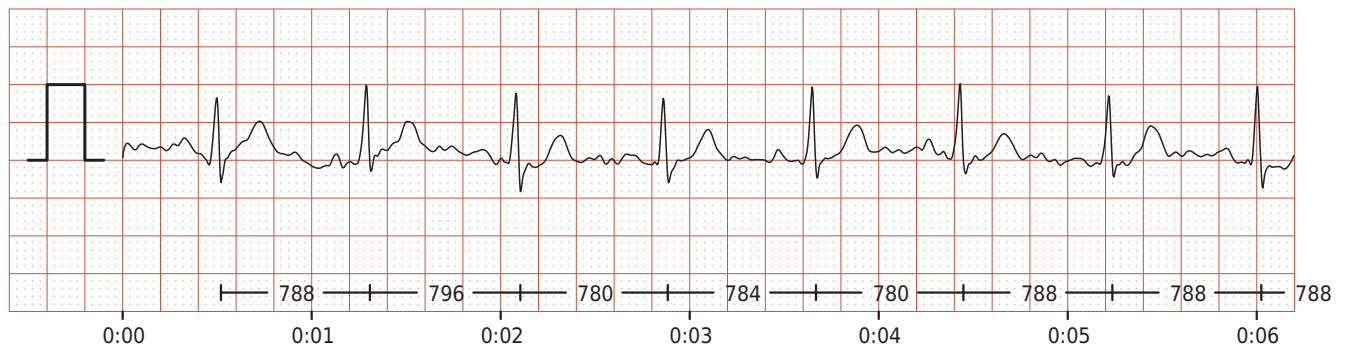ЧСС макс.: **85/мин**

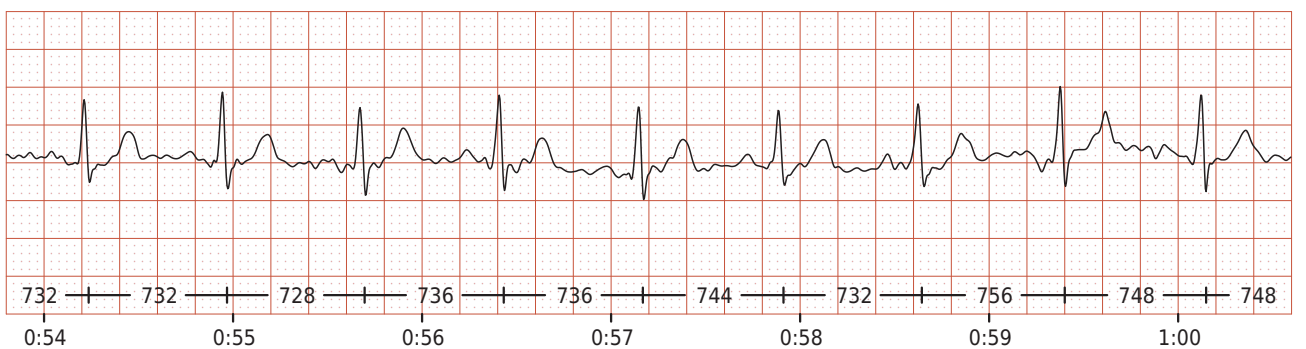
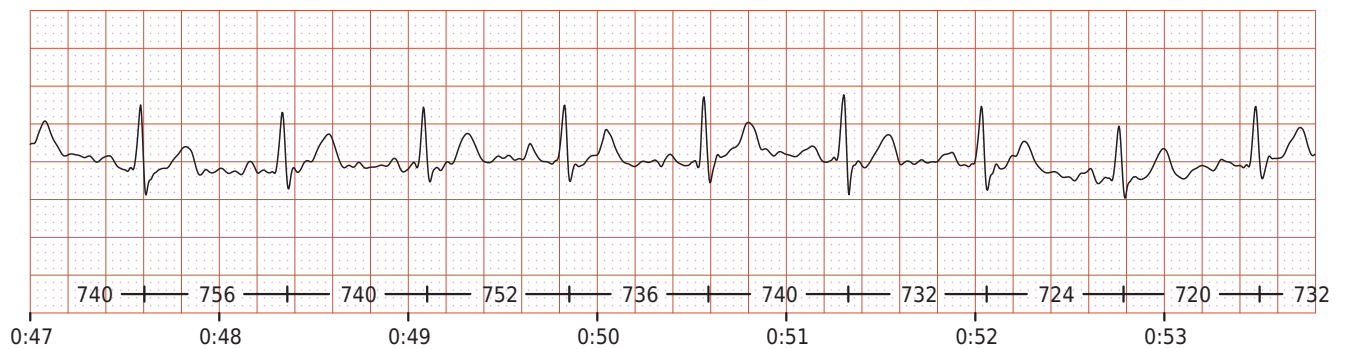
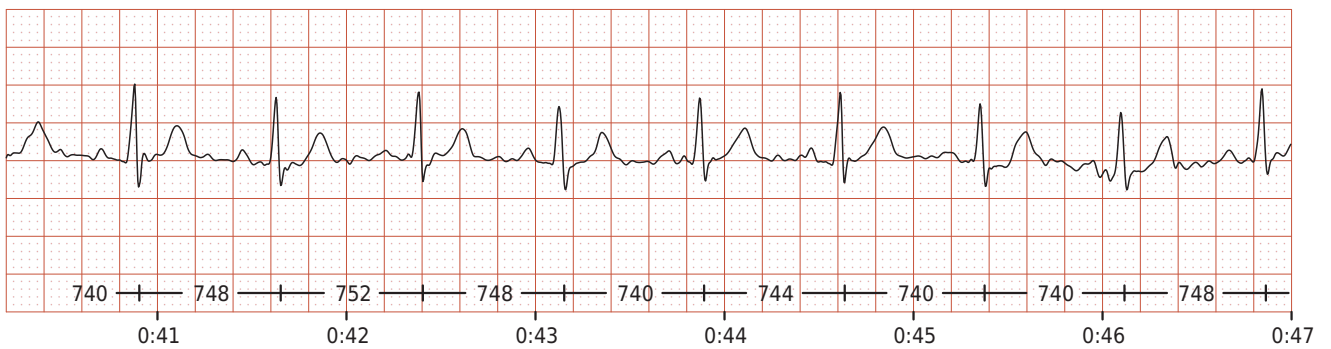
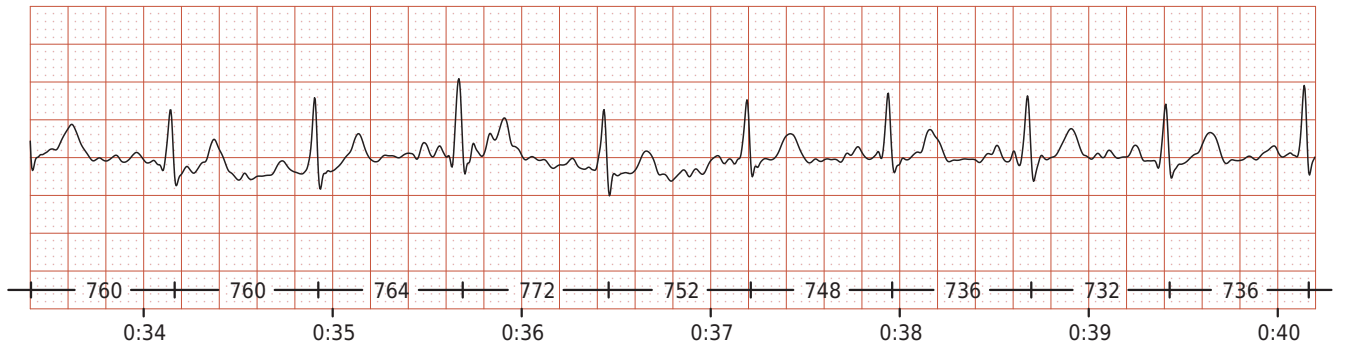
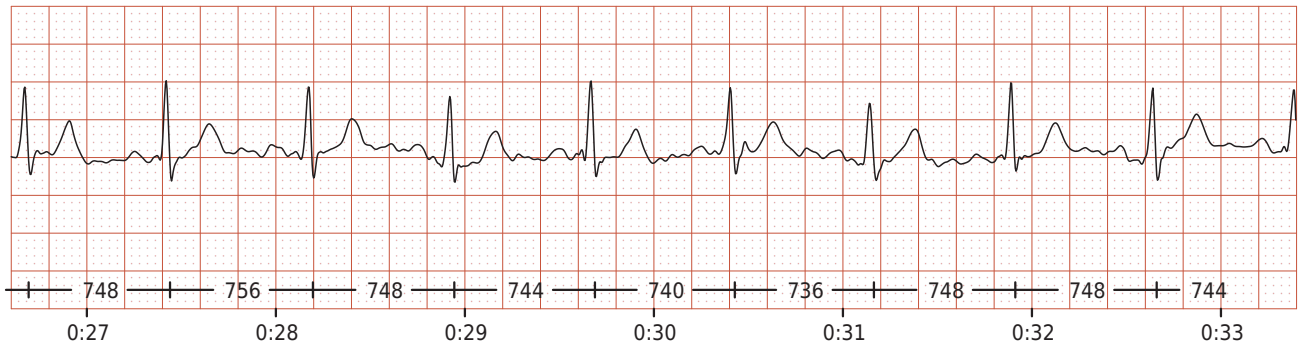
Ритм: **Синусовый**

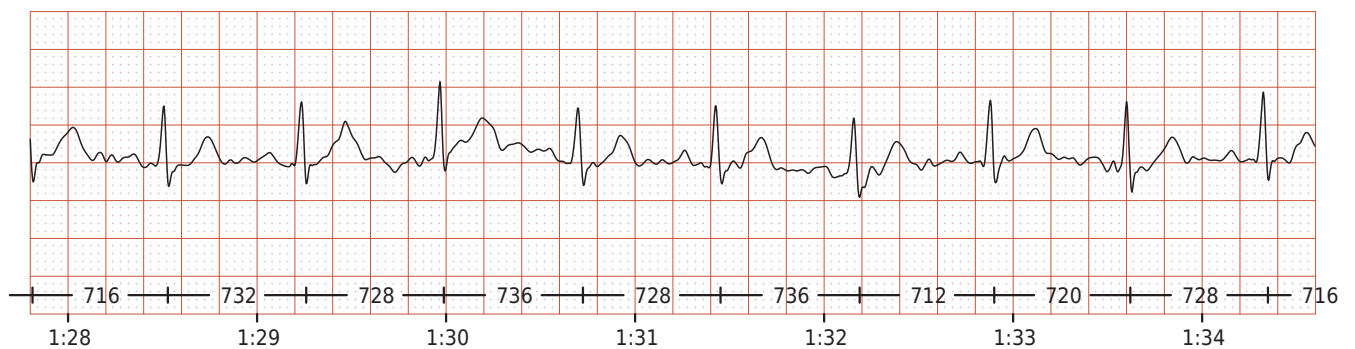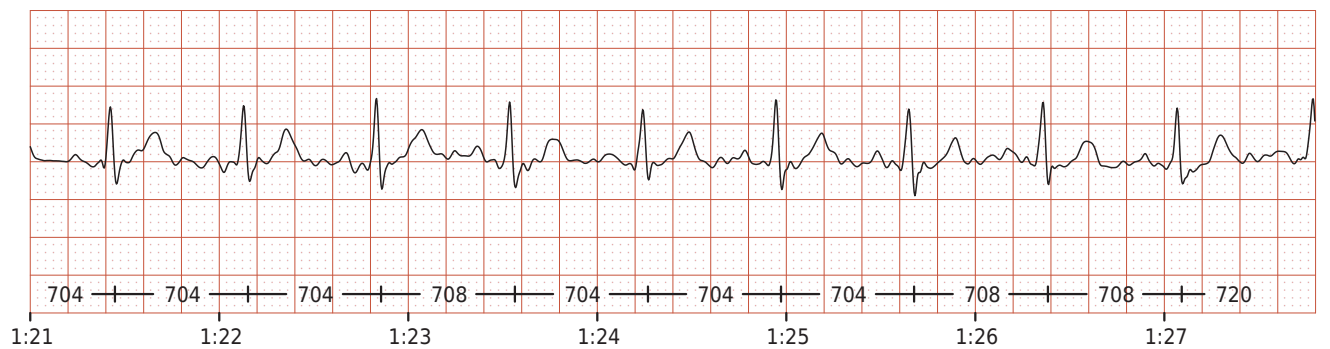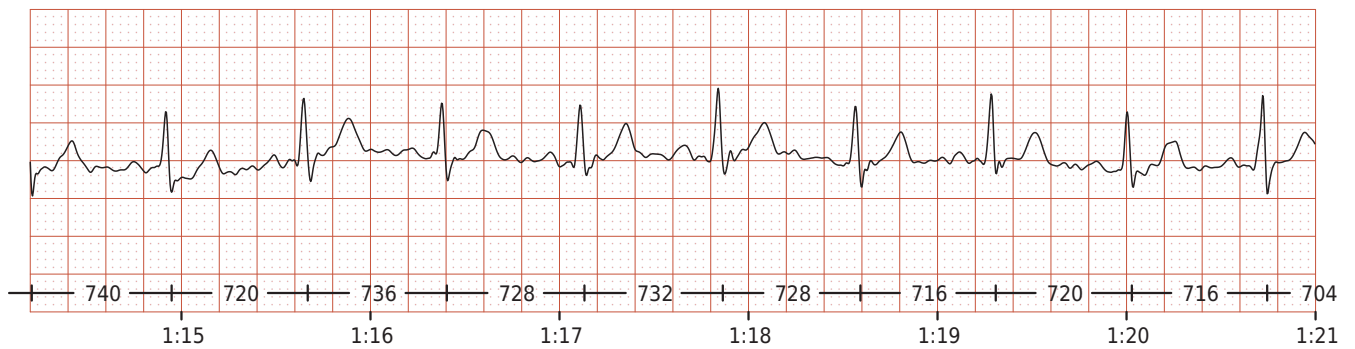
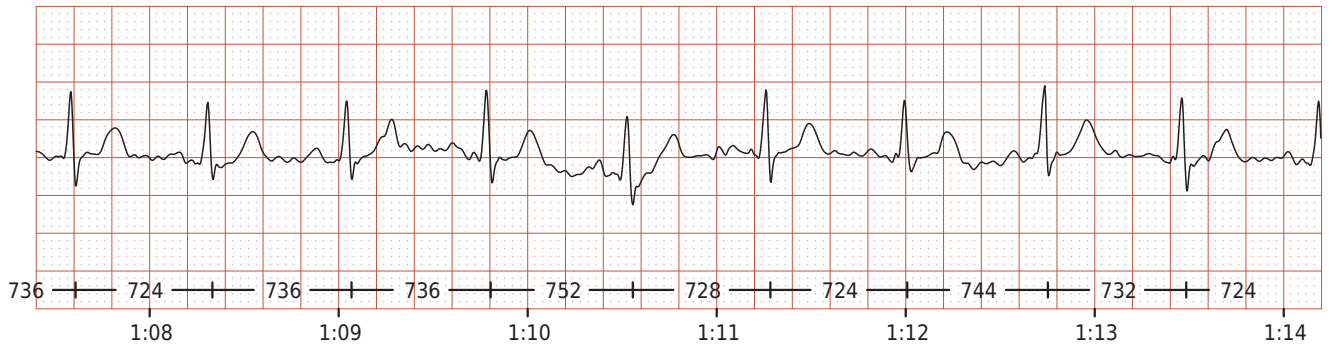
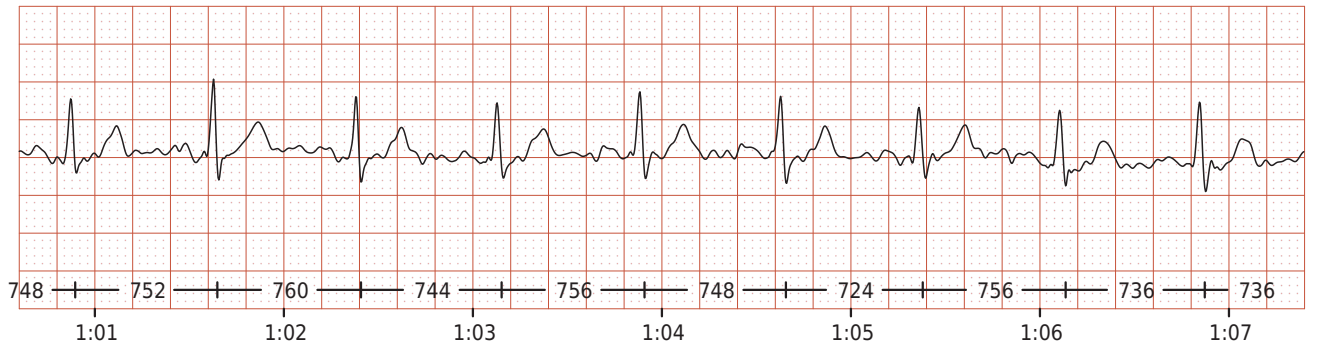
ЖЭС: **0**

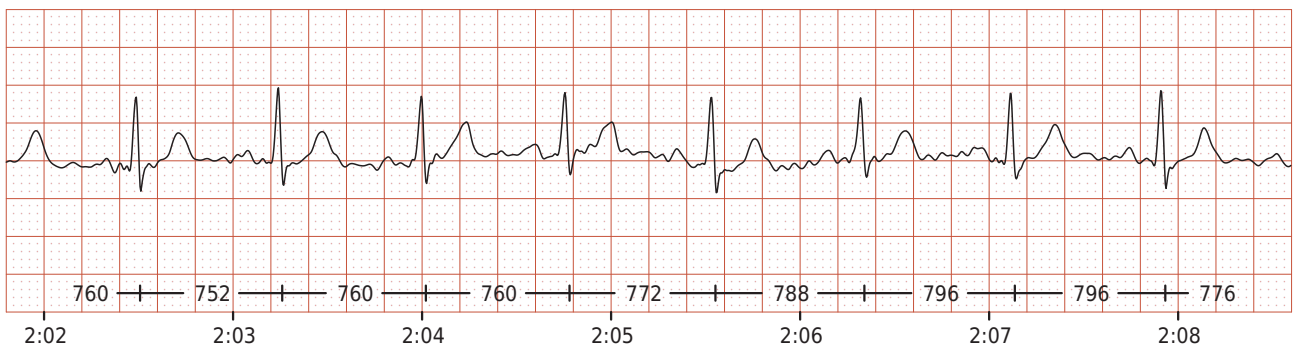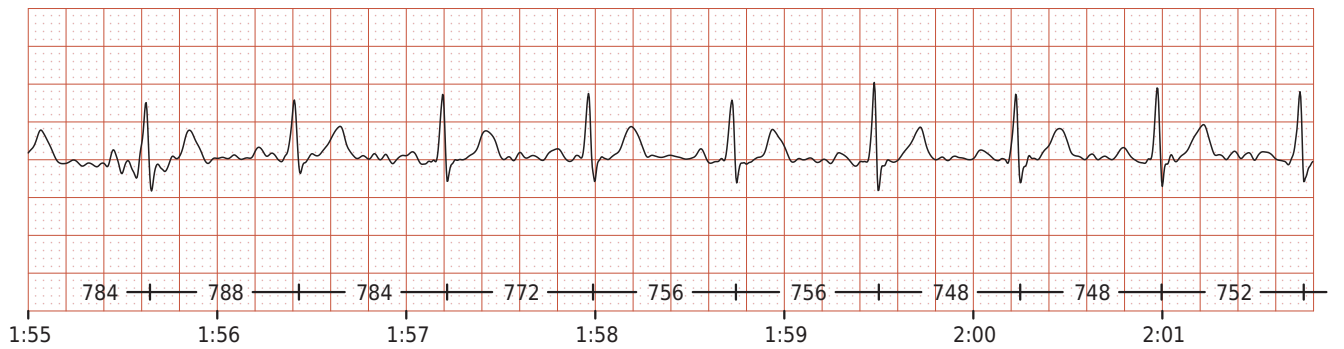
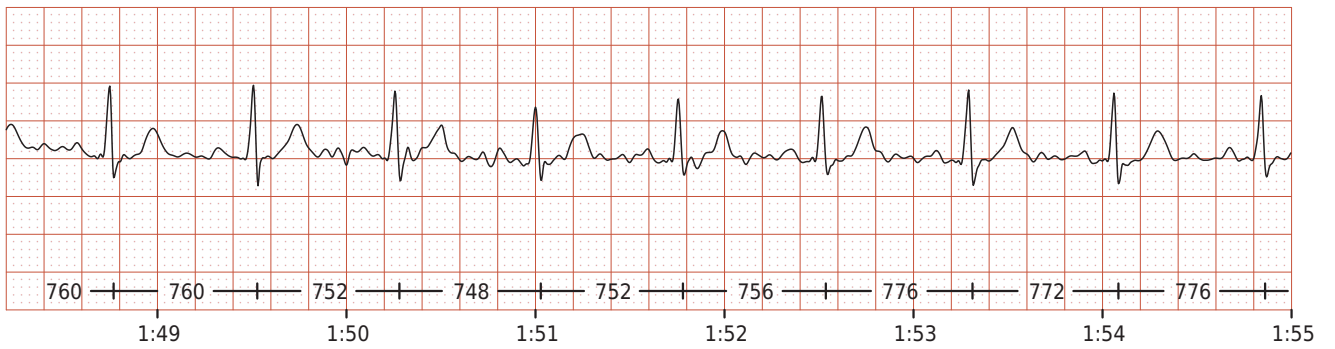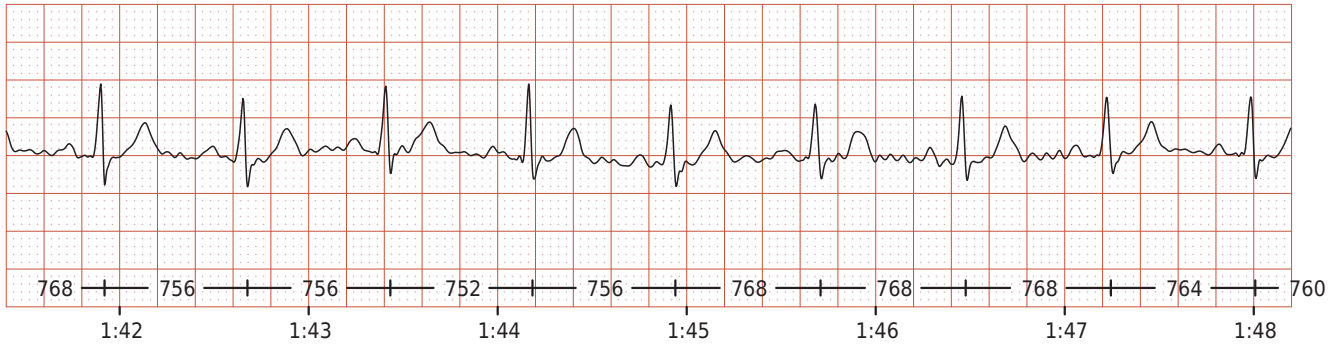
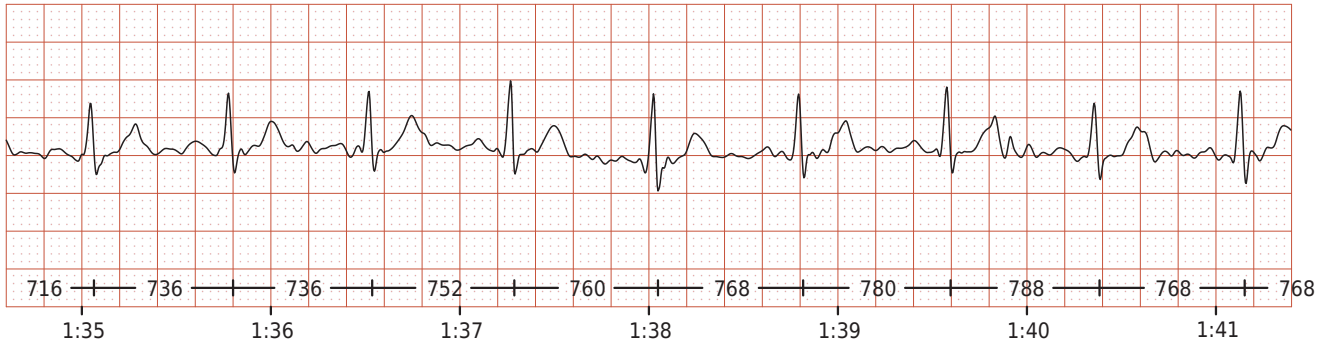
НЖЭС: **0**

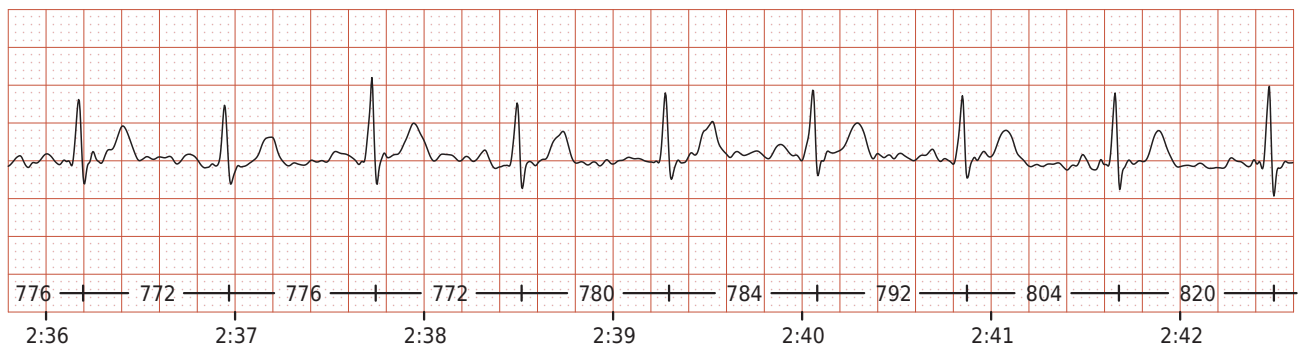
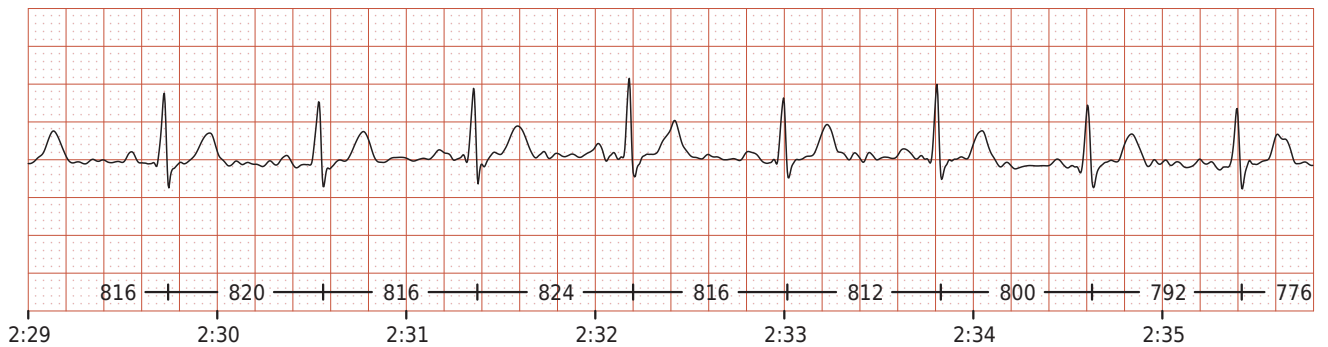
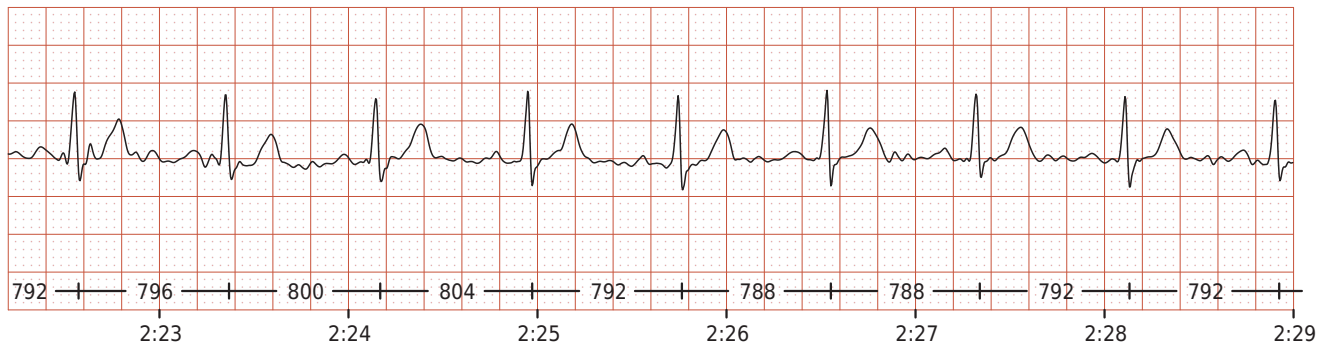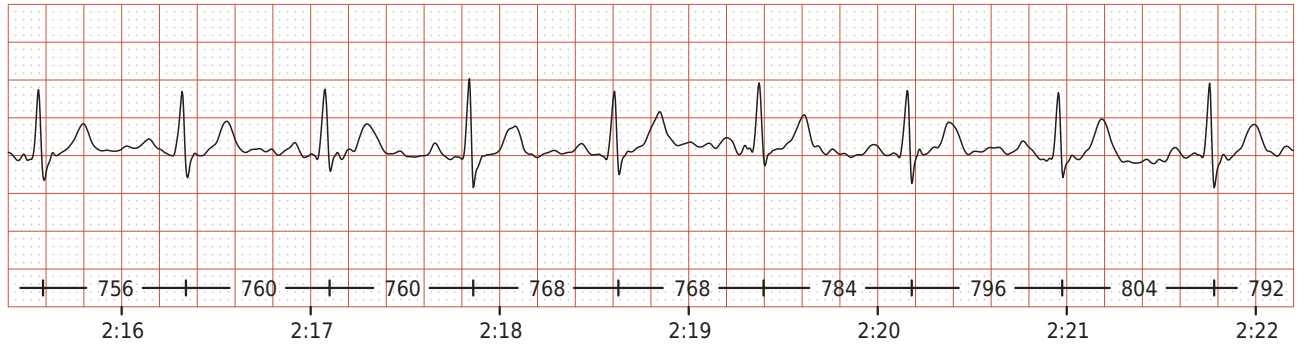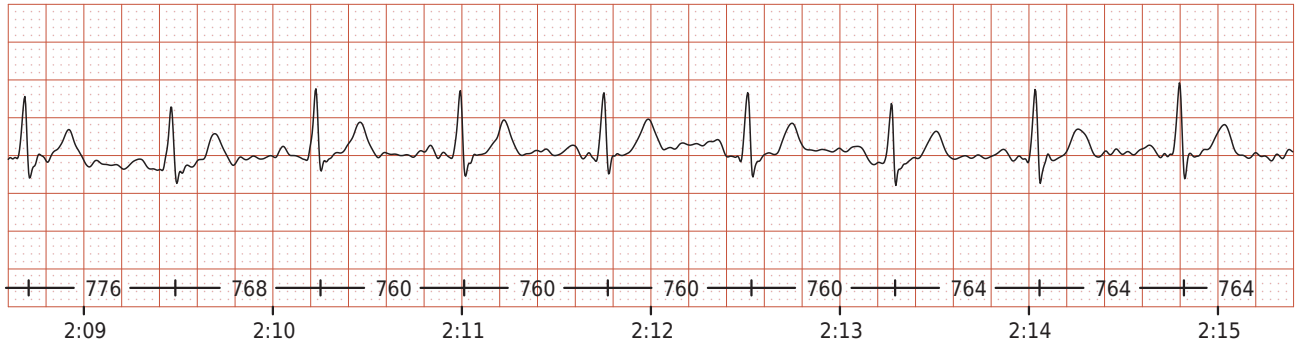
Фильтр: 50 Гц; 0.5-35 Гц; ЦФВЧ, 25 мм/с 10 мм/мВ

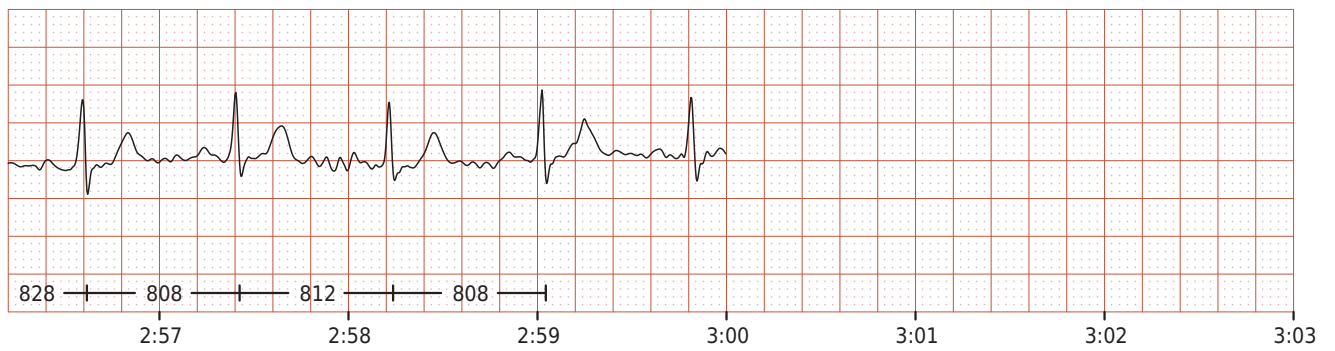
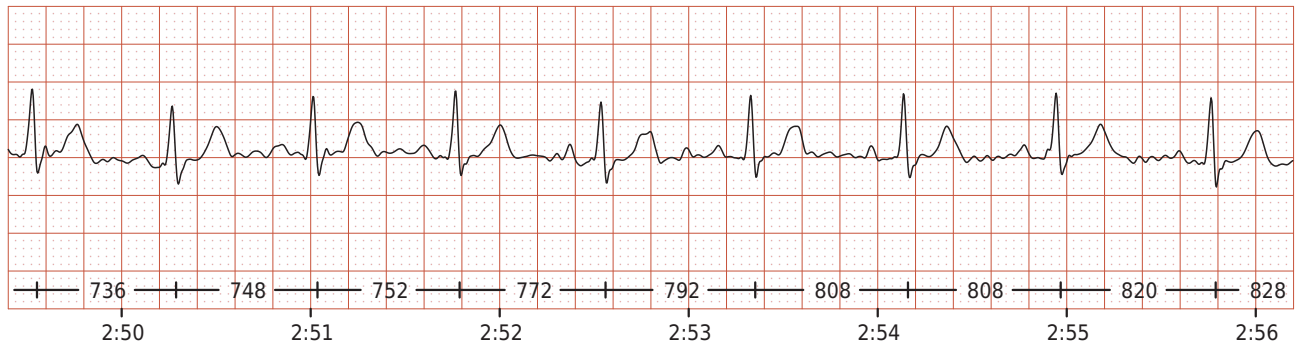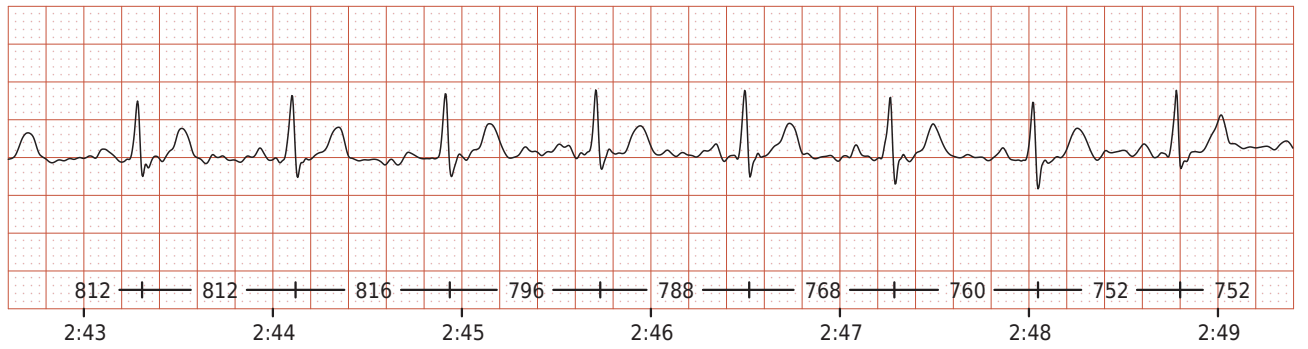






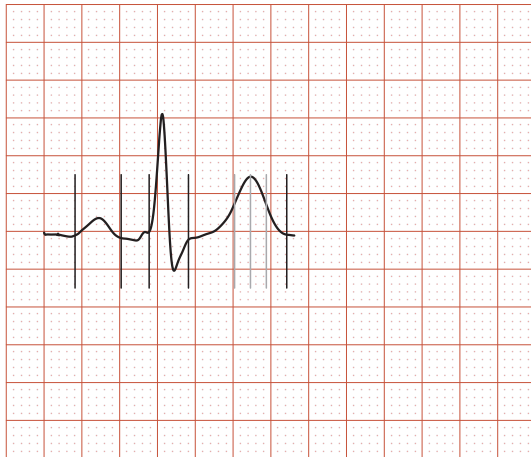






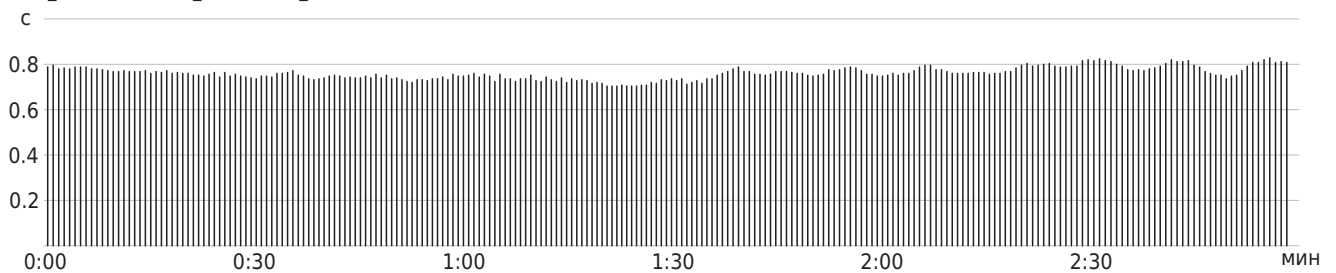
Кардиоцикл

50 мм/с 20 мм/мВ

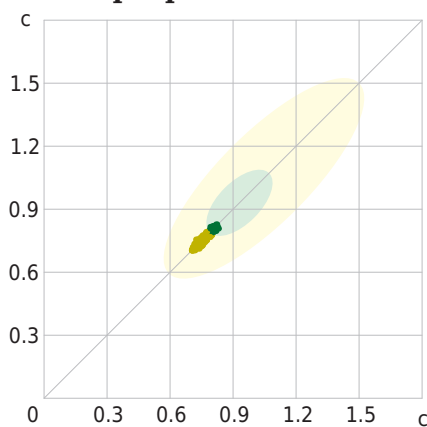


RR	=	756	МС
P	=	122	МС
PQ	=	196	МС
QRS	=	104	МС
QTc	=	421	МС
QT	=	364	МС

Кардиоинтервалограмма

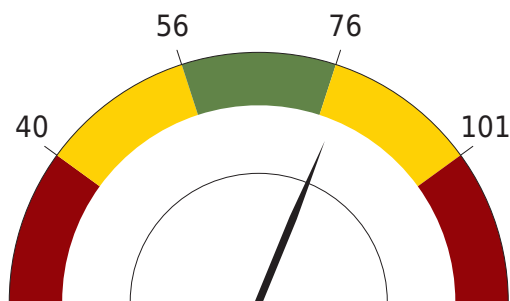


Скаттерограмма



Параметры ВСР

HR	=	79	/МИН	LF	=	97	МС ²
Extr	=	0	ШТ.	HF	=	13	МС ²
SDNN	=	27	МС	LF/HF	=	8.1	
TP	=	581	МС ²	SI	=	147.4	о.е.



Пульс: умеренная тахикардия