

ФИО: _____

Пол: **Женский**

Возраст: **68**

Вес: **70**

Рост: **163**

Дата: **2020-12-28**

Время: **08:32:23 UTC+3**

ЧСС: **85/мин**

ЧСС мин.: **79/мин**

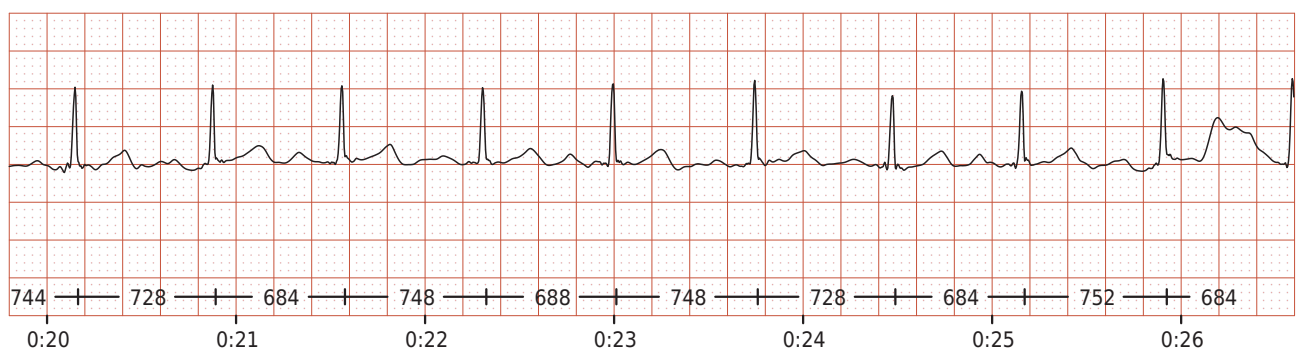
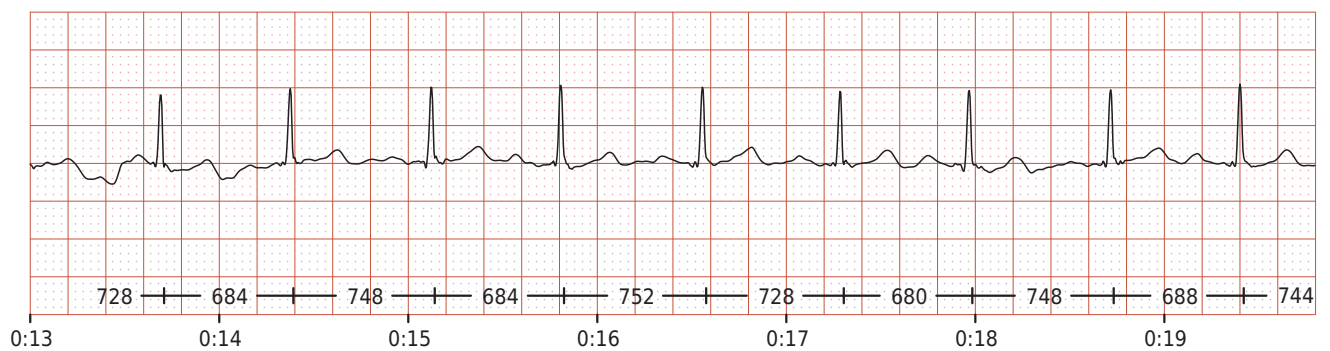
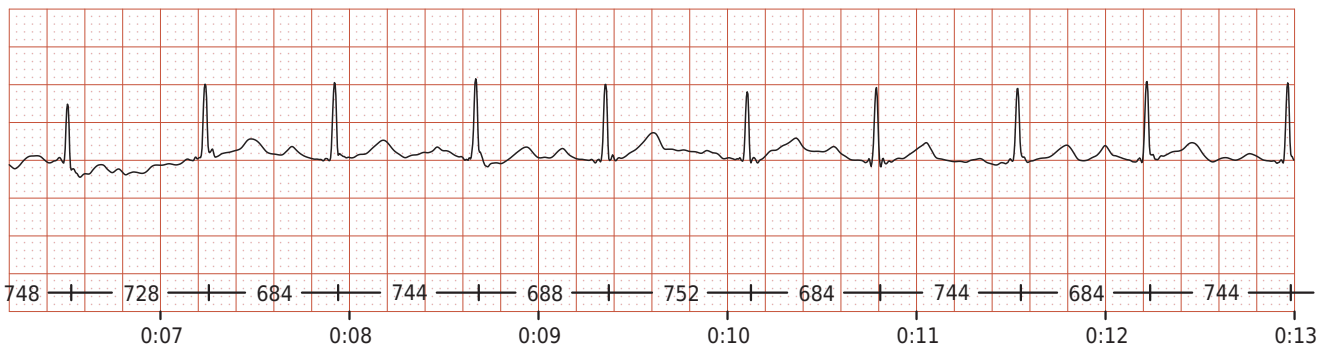
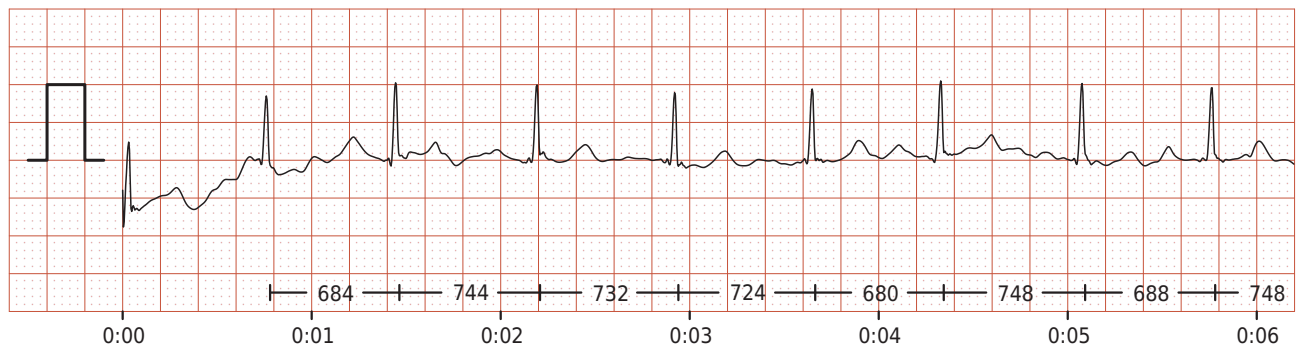
ЧСС макс.: **91/мин**

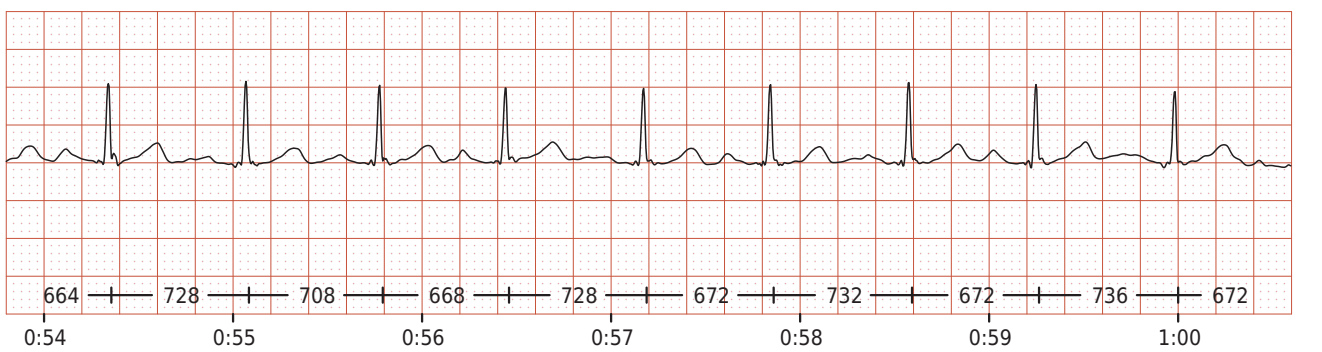
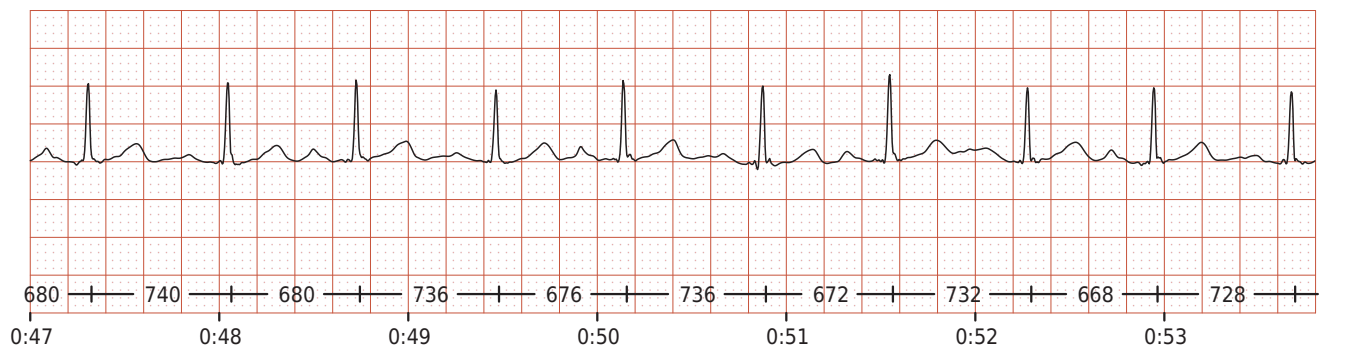
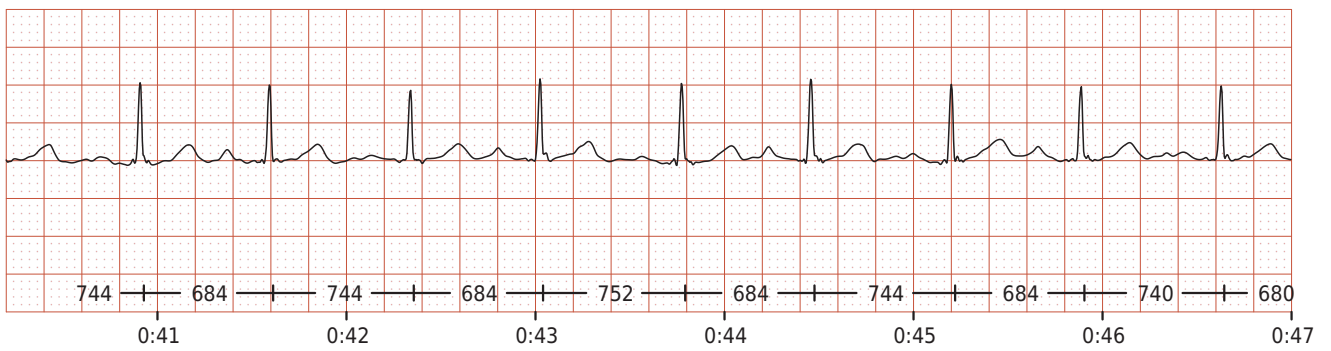
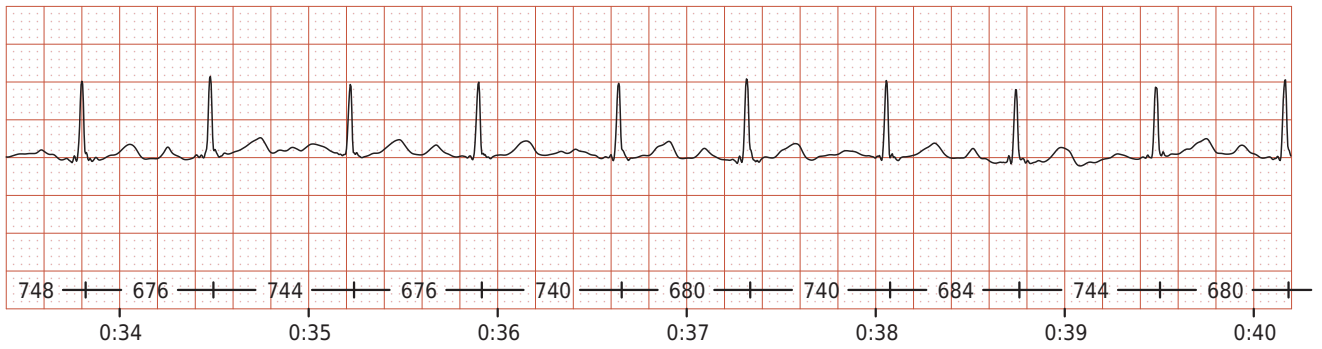
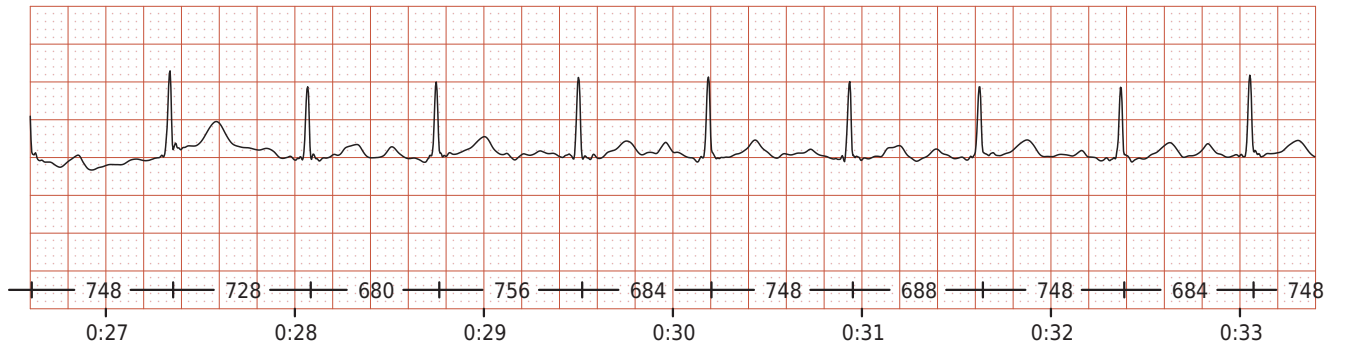
Ритм: **Синусовый**

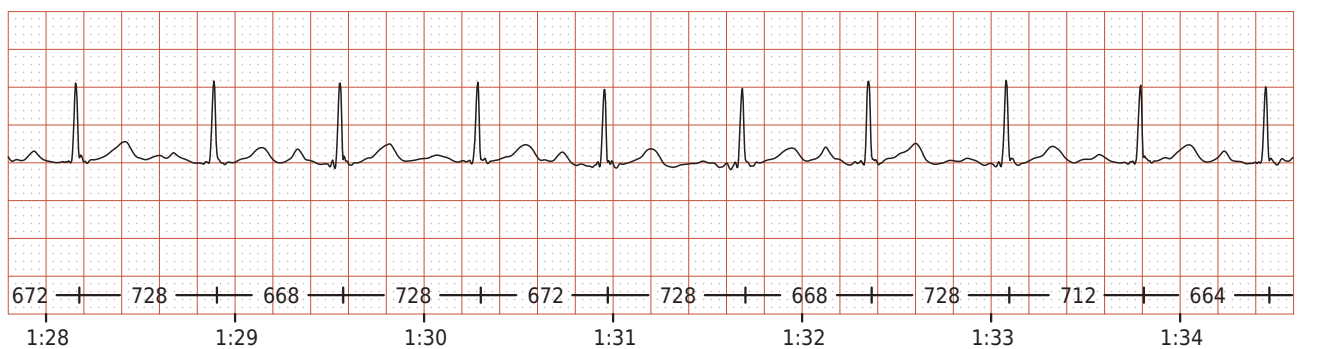
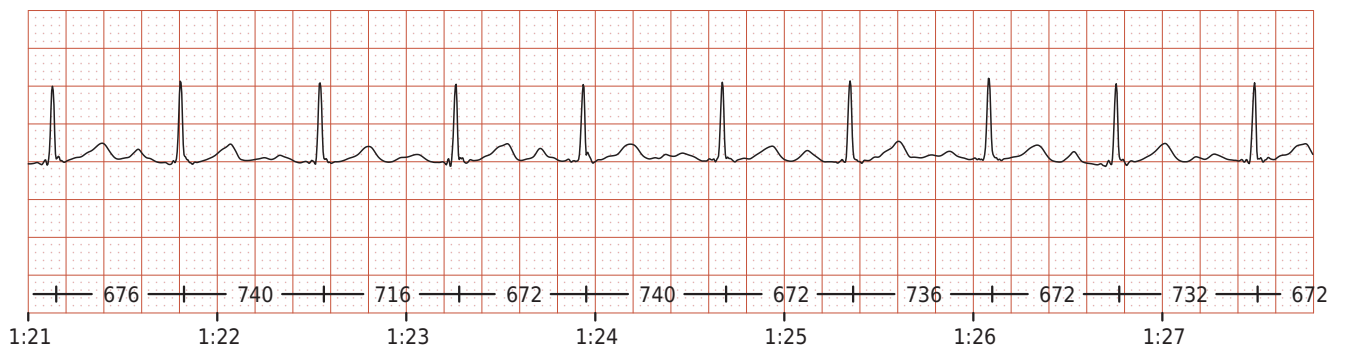
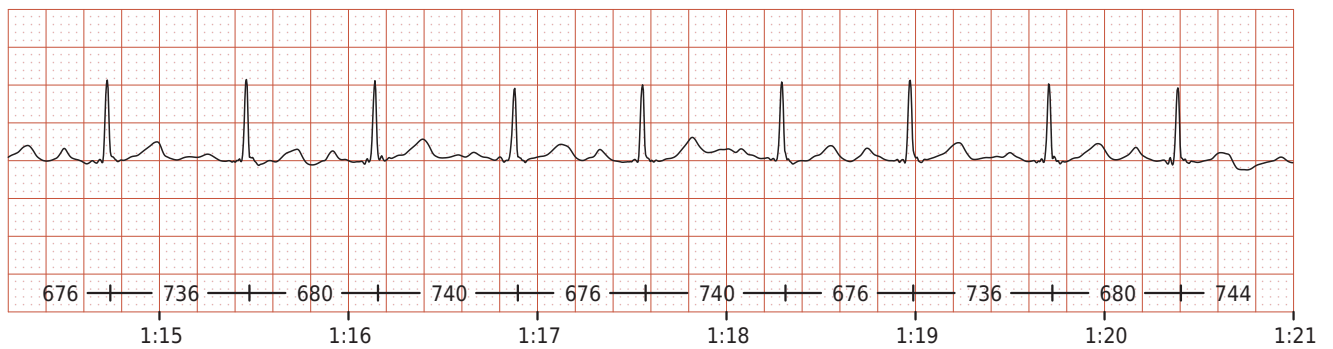
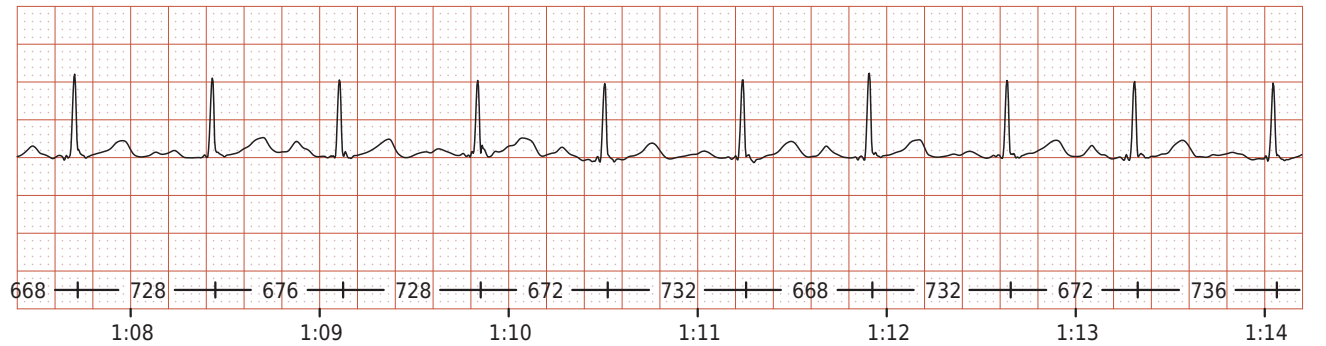
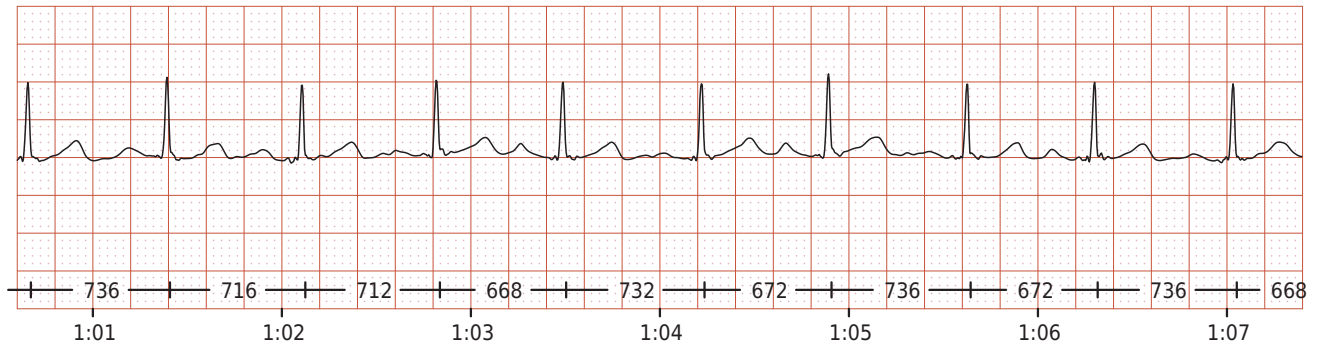
ЖЭС: **0**

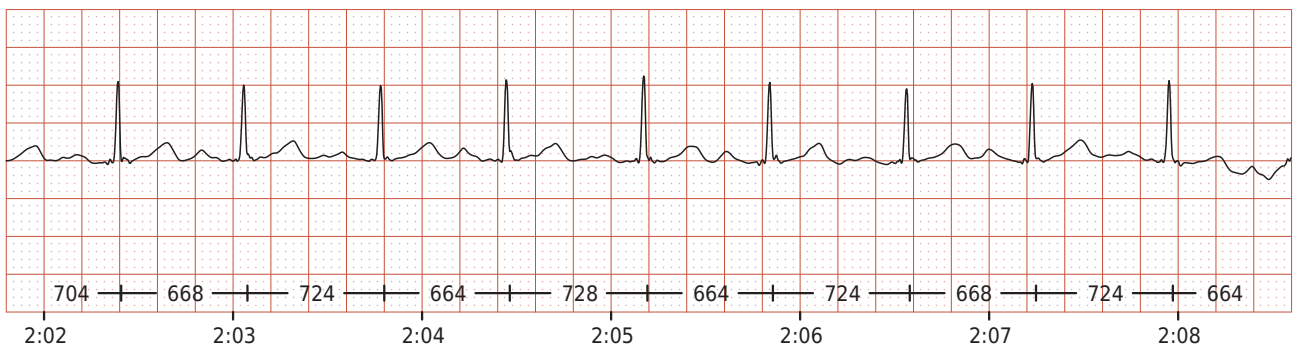
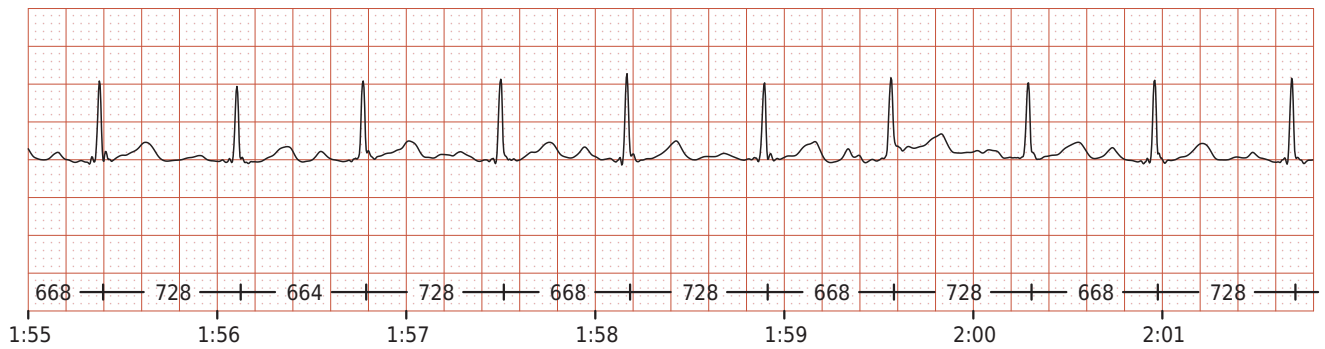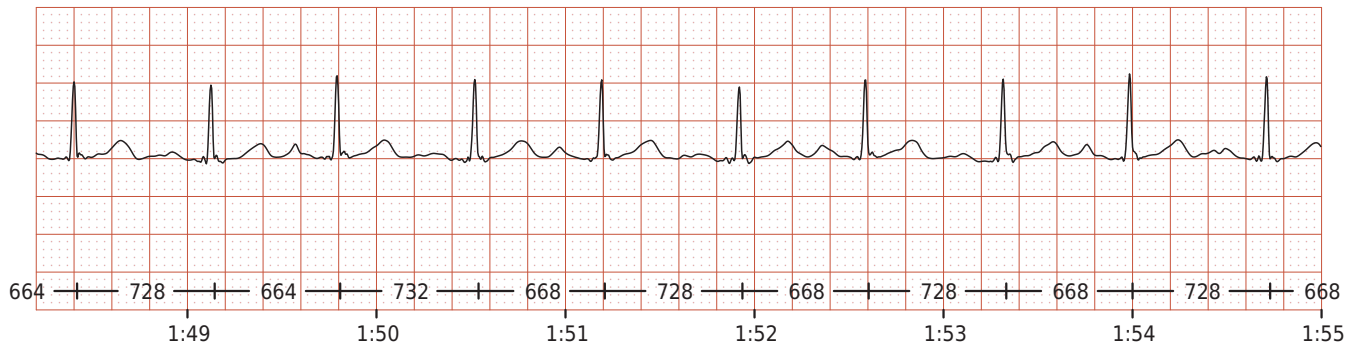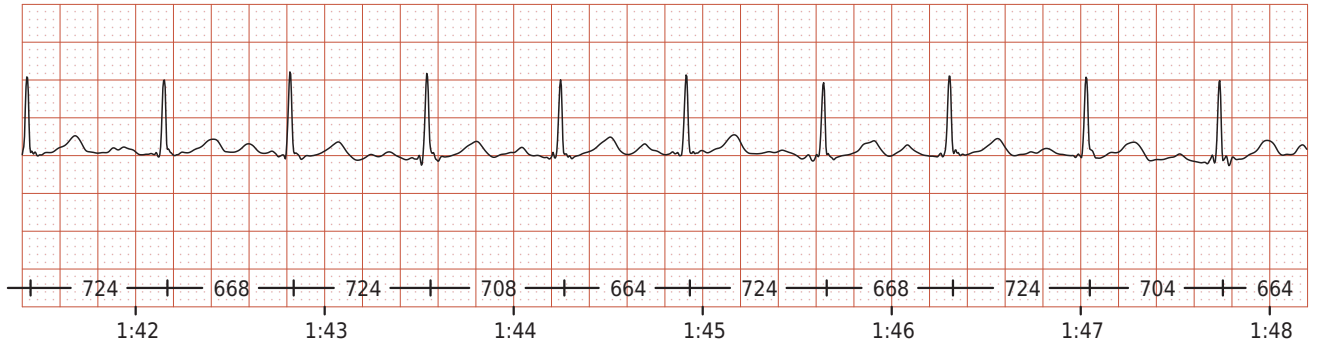
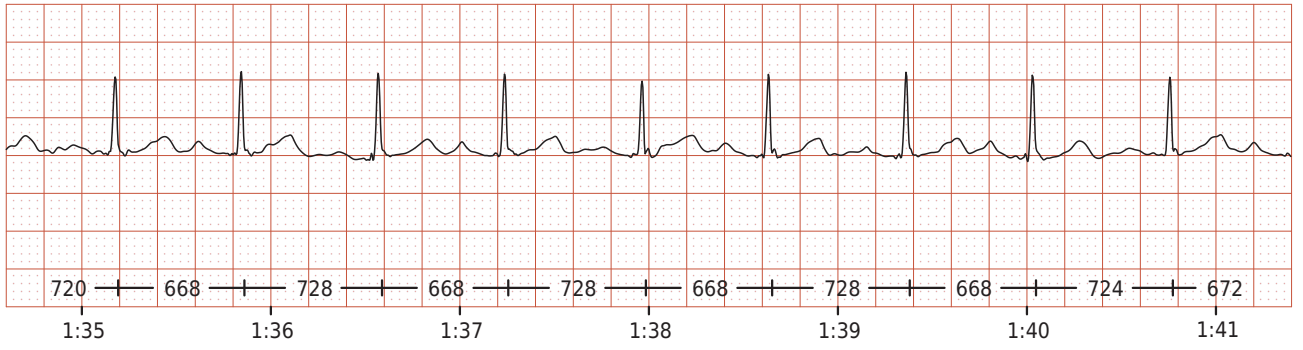НЖЭС: **0**

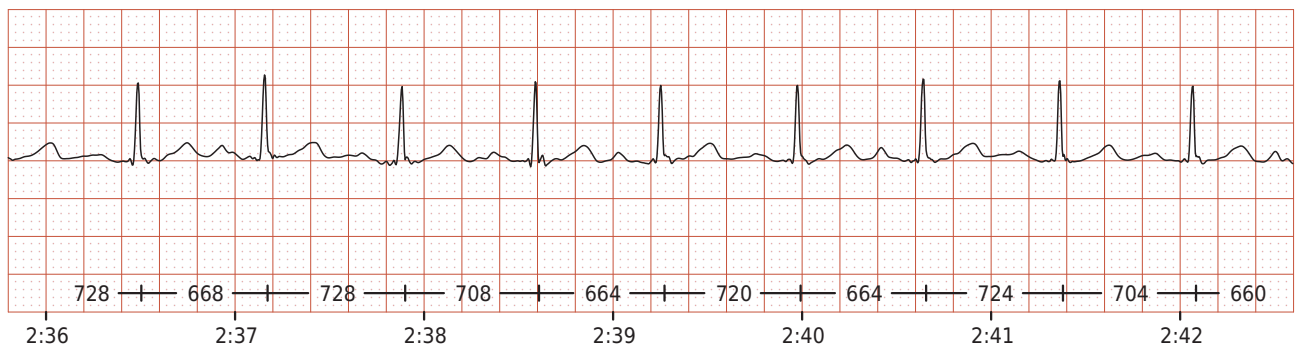
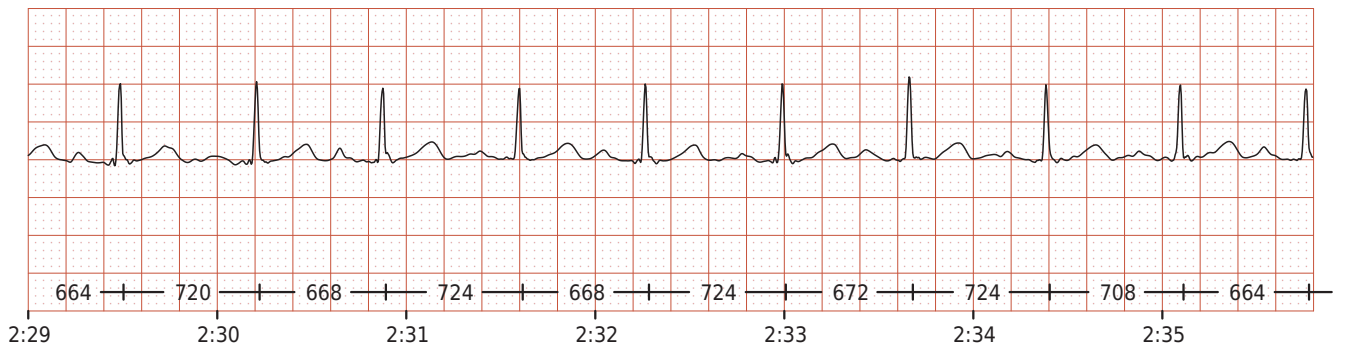
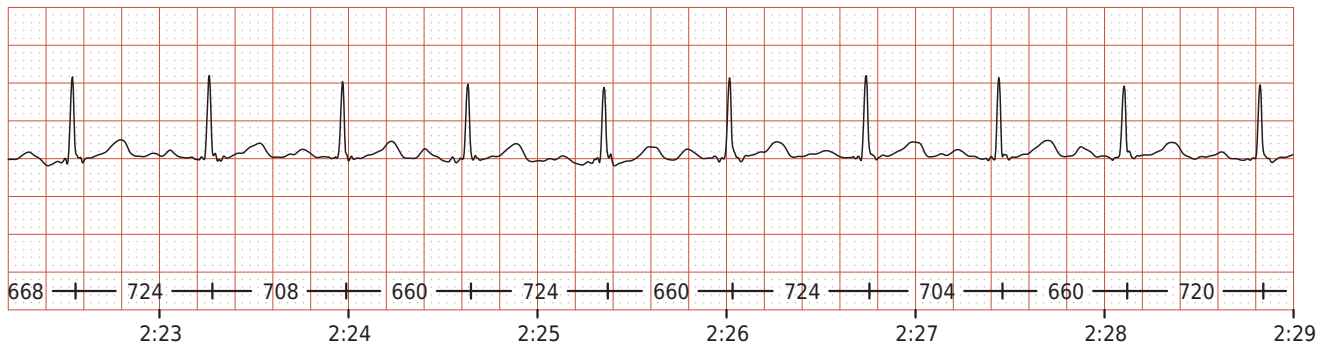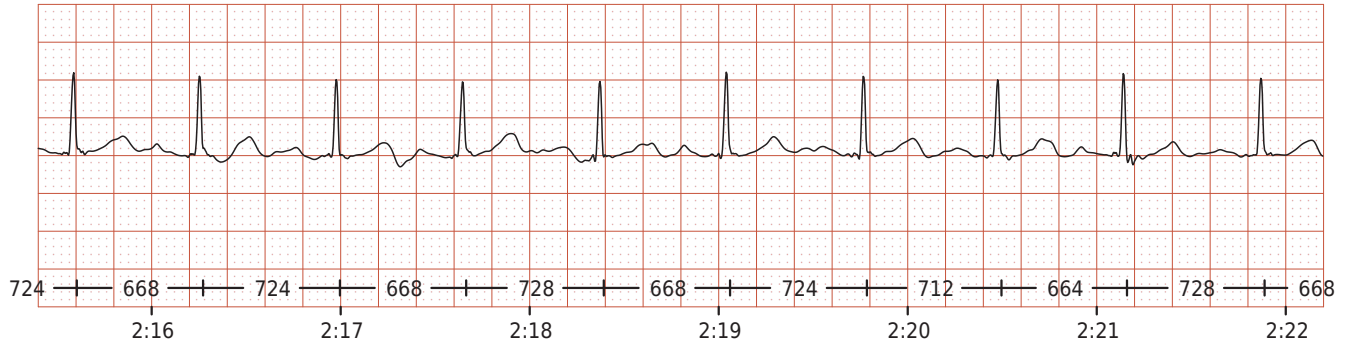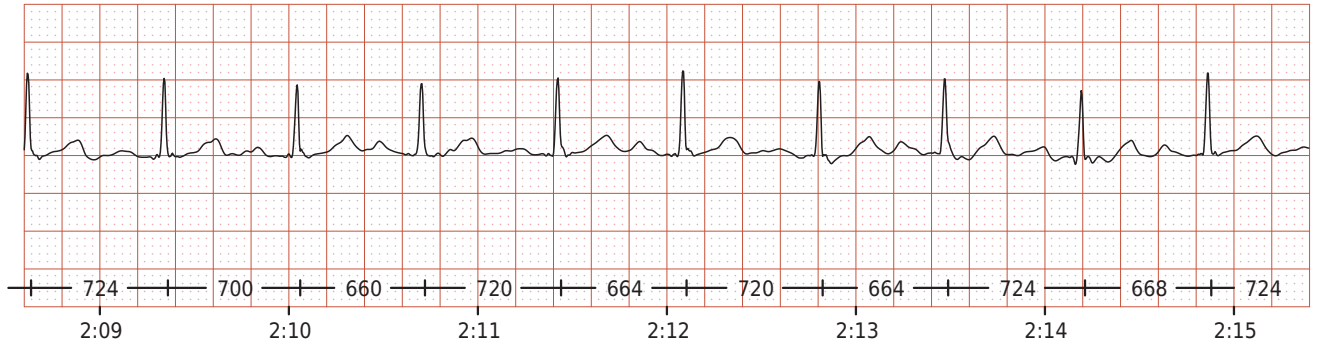Фильтр: 50 Гц; 0.5-35 Гц; ЦФВЧ, 25 мм/с 10 мм/мВ

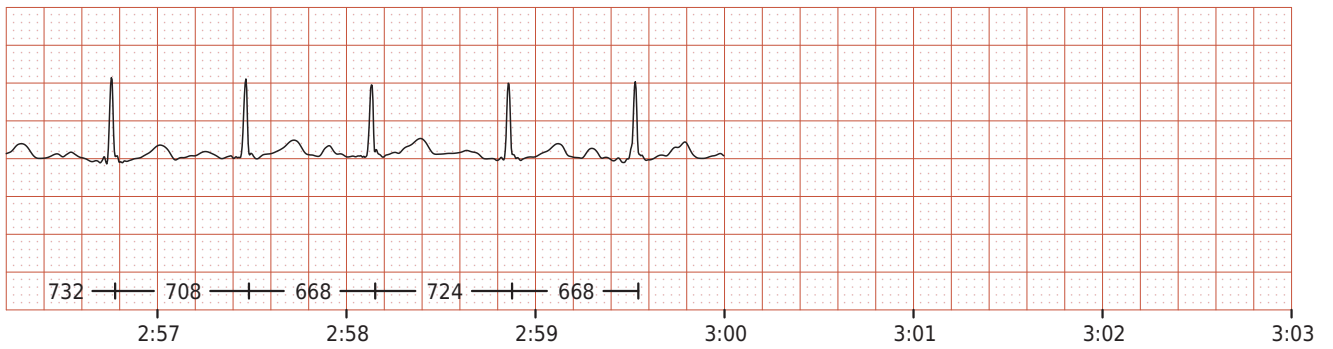
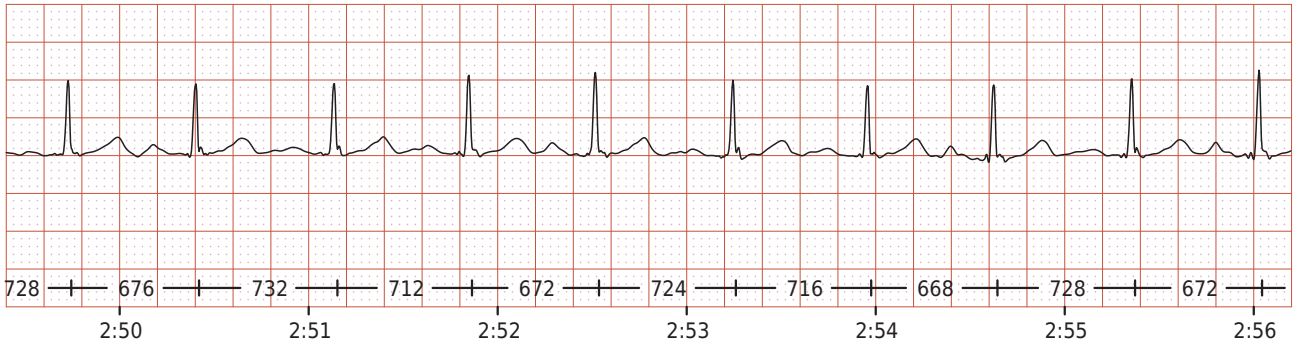
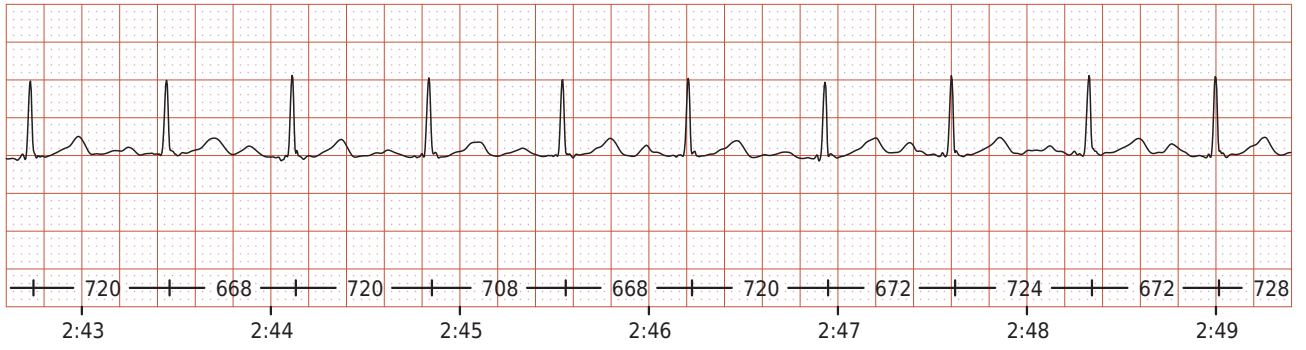




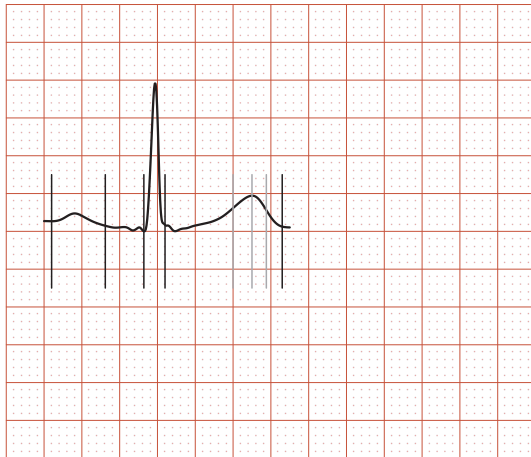






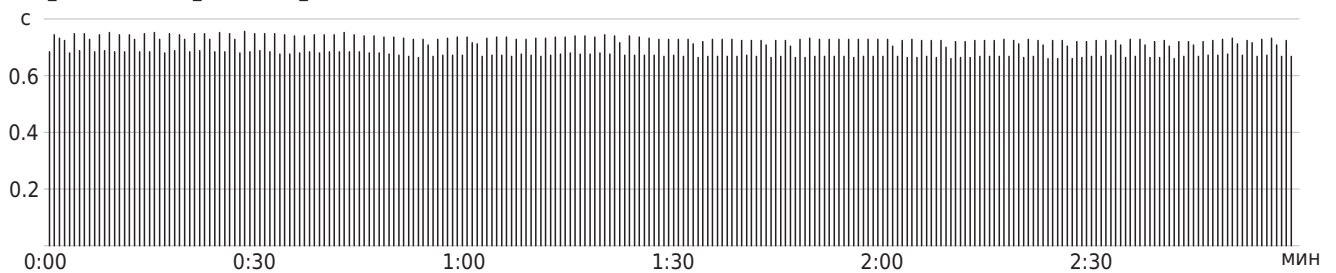
Кардиоцикл

50 мм/с 20 мм/мВ

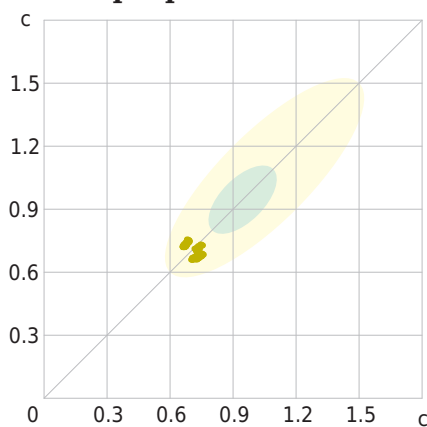


RR	=	696	МС
P	=	142	МС
PQ	=	244	МС
QRS	=	56	МС
QTc	=	441	МС
QT	=	366	МС

Кардиоинтервалограмма

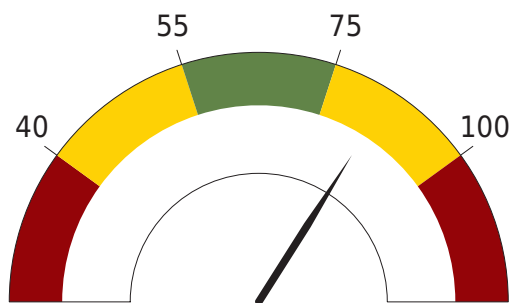


Скаттерограмма



Параметры ВСР

HR	=	85	/МИН	LF	=	6	МС ²
Extr	=	0	ШТ.	HF	=	22	МС ²
SDNN	=	30	МС	LF/HF	=	0.3	
TP	=	39	МС ²	SI	=	113.1	о.е.



Пульс: умеренная тахикардия